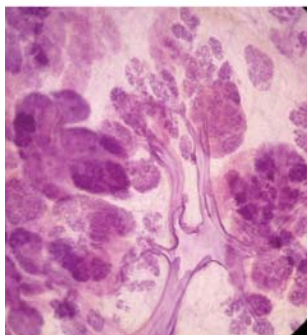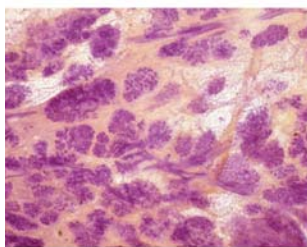


3D image of the breast tissue



The normal TDLUs have bud-like acini



**HELLENIC BREAST  
IMAGING SOCIETY**

Active Member of Senologic  
International Society

## *BREAST SEMINAR*

Organized by the

**Hellenic Breast Imaging Society**

*President: ATHINA VOURTSIS, MD, PhD*

*Radiologist*

## Advanced Course on Multimodality Detection and Diagnosis of Breast Diseases

**LÁSZLÓ TABÁR, MD, FACR (Hon)**

*Professor emeritus of Radiology*

*Falun, Sweden*

**June 3-5, 2016**

**ATHENS, Greece**

**Hotel Divani Caravel**

*Designed for:*

**Radiologists • Surgeons • Pathologists**

Implications of mammography, MRI, breast ultrasound and  
interventional methods in your practice

***This course provides extensive knowledge about diagnostic  
breast imaging, differential diagnosis of breast diseases,  
implications for management and newest diagnostic technologies***

**Event Secretariat:**  Events & Travel Solutions

**E.T.S. Events & Travel Solutions S.A.**

154 El. Venizelou Str N. Smyrni, Athens, Greece, 171 22 • Tel.: +30 210 98 80 032, Fax.: +30 210 98 81 303

E-mail: ets@events.gr, ets@otenet.gr • Website: www.events.gr



2016

BREAST SEMINAR of the  
Hellenic Breast Imaging Society  
Advanced Course on Multimodality Detection and  
Diagnosis of Breast Diseases

László Tabár, MD., FACR (Hon)  
*Course Director*

## FACULTY



**László Tabár, MD., FACR. (Hon).**

Invited Speaker

*Professor emeritus of Radiology,  
Department of Mammography,  
Falun, Sweden*



Images from the non-profit Tabar Foundation for Research and Education for Breast Cancer

[www.tabarfoundation.org](http://www.tabarfoundation.org)